

# $^1\text{H}$ MRS Assessment of Hepatic Fat Content: Comparison Between Normal- and Excess-weight Children and Adolescents

Elizaveta Chabanova, PhD, Cilius Esmann Fonvig, PhD, Christine Bøjsøe, MD, Jens-Christian Holm, PhD, Henrik S. Thomsen, Dr Med Sci

## Abbreviations and Acronyms

<b>BMI</b>
body mass index
<b>CT</b>
computed tomography
<b>LFC</b>
liver fat concentration
<b>LFSF</b>
liver fat signal fraction
<b>MRS</b>
magnetic resonance spectroscopy
<b>MR</b>
magnetic resonance
<b>NAFLD</b>
nonalcoholic fatty liver disease
<b>PRESS</b>
point resolved spectroscopy
<b>SD</b>
standard deviation
<b>SDS</b>
standard deviation score
<b>TE</b>
echo time
<b>TR</b>
repetition time
<b>TSE</b>
turbo spin echo
<b>VOI</b>
volume of interest

**Rationale and Objectives:** The purpose of the present study was to obtain a cutoff value of liver fat content for the diagnosis of hepatic steatosis by comparing magnetic resonance (MR) spectroscopy results in children and adolescents with normal and excess weight.

**Materials and Methods:** The study included 420 children and adolescents (91 normal-weight, 99 overweight, and 230 obese) 8–18 years of age. Proton magnetic resonance spectroscopy was performed with a 3T MR system using point resolved spectroscopy with series echo times.

**Results:** The mean absolute mass concentration of liver fat was obtained:  $0.5 \pm 0.04\%$  in normal-weight boys;  $0.5 \pm 0.03\%$  in normal-weight girls;  $0.9 \pm 0.16\%$  in boys with overweight;  $1.1 \pm 0.24\%$  in girls with overweight;  $1.7 \pm 0.24\%$  in boys with obesity; and  $1.4 \pm 0.21\%$  in girls with obesity.

The cutoff value of absolute mass concentration of liver fat for hepatic steatosis was found to be 1.5%. Based on this cutoff value, hepatic steatosis was diagnosed in 16% of boys with overweight, 11% of girls with overweight, 32% of boys with obesity, and 27% of girls with obesity.

**Conclusions:** Proton magnetic resonance spectroscopy was successfully applied to obtain the cutoff value of absolute mass concentration of liver fat for the diagnosis of hepatic steatosis in children and adolescents. Children and adolescents with obesity have higher risk of hepatic steatosis than their peers with overweight.

**Key Words:** Adolescents; children; magnetic resonance; obesity; spectroscopy; steatosis.

© 2017 The Association of University Radiologists. Published by Elsevier Inc. All rights reserved.

Acad Radiol 2017; 24:982–987

From the Department of Diagnostic Radiology, Copenhagen University Hospital Herlev Gentofte, Herlev Ringvej 75, DK-2730 Herlev (E.C., H.S.T.); The Children's Obesity Clinic, Department of Pediatrics, Copenhagen University Hospital Holbæk, Holbæk (C.E.F., C.B., J.-C.H.); The Novo Nordisk Foundation Center for Basic Metabolic Research, Section of Metabolic Genetics, University of Copenhagen, Copenhagen (C.E.F., C.B., J.-C.H.); Faculty of Health Sciences, University of Copenhagen, Copenhagen, Denmark (J.-C.H., H.S.T.). Received September 23, 2016; revised February 13, 2017; accepted February 14, 2017. **Address correspondence to:** E.C. e-mail: [Elizaveta.Chabanova@regionh.dk](mailto:Elizaveta.Chabanova@regionh.dk)

© 2017 The Association of University Radiologists. Published by Elsevier Inc. All rights reserved.  
<http://dx.doi.org/10.1016/j.acra.2017.02.010>

## INTRODUCTION

Obesity has become a growing health challenge all over the world, beginning at early age in children and progressing into adulthood (1,2). One of the major complications caused and worsened by obesity is nonalcoholic fatty liver disease (NAFLD). NAFLD ranges from simple steatosis through steatohepatitis and fibrosis to end-stage liver disease (cirrhosis) and is defined as triglyceride accumulation in hepatocytes exceeding 5% of the liver weight (3,4). Liver biopsy is the gold standard of diagnosis and severity assessment of NAFLD (5,6). However, it is an invasive procedure associated with serious risks (7).

Proton magnetic resonance spectroscopy (<sup>1</sup>H MRS) has in recent years been recognized as an alternative noninvasive technique for the measurement of fat content in the liver (8–12). A number of studies have been devoted to the assessment of hepatic steatosis, but there is a disagreement in the literature regarding the cutoff values ranging from 1.8% to 5.6% (10,11,13,14). The cutoff values are dependent on acquisition parameters and on fat fraction calculations. Only few publications mention a cutoff value for absolute mass concentration of liver fat (LFC) measured by <sup>1</sup>H MRS in children and adolescents (12,13,15). We found no published studies that have compared LFC assessed in children with obesity to LFC assessed in a large group of normal-weight, healthy children.

The purpose of the present study was to obtain a cutoff value of the liver fat content for the diagnosis of hepatic steatosis by comparing MRS results in normal- and excess-weight children and adolescents.

## MATERIALS AND METHODS

### Study Population

A total of 420 children and adolescents 8–18 years of age participated in the study (Table 1). The overweight and obese groups were enrolled from The Children's Obesity Clinic (16–18), and the normal-weight group was recruited from schools in the same geographical region. The relative weight status of the three groups was defined according to age- and sex-adjusted body mass index (BMI) charts (19,20): the normal-weight group with a BMI standard deviation score (SDS) below 1.28; the overweight group with a BMI SDS between 1.28 and 2.33; and the obese group with a BMI SDS over 2.33.

Informed assent was provided by all study participants. Written informed consent was obtained from all study participants older than 18 years of age and from parents of children younger than 18 years. The study was approved by the Ethics Committee of Region Zealand, Denmark (ID-no.: SJ-104 and SJ-98), by the Data Protection Agency (ID: REG-06-2014), and is registered at [ClinicalTrials.gov](https://www.clinicaltrials.gov) (ID: NCT00928473).

### Magnetic Resonance Examination

MR measurements were performed on a 3T Achieva MR imaging system (Philips Medical Systems, Best, the Netherlands)

TABLE 1. Study Population

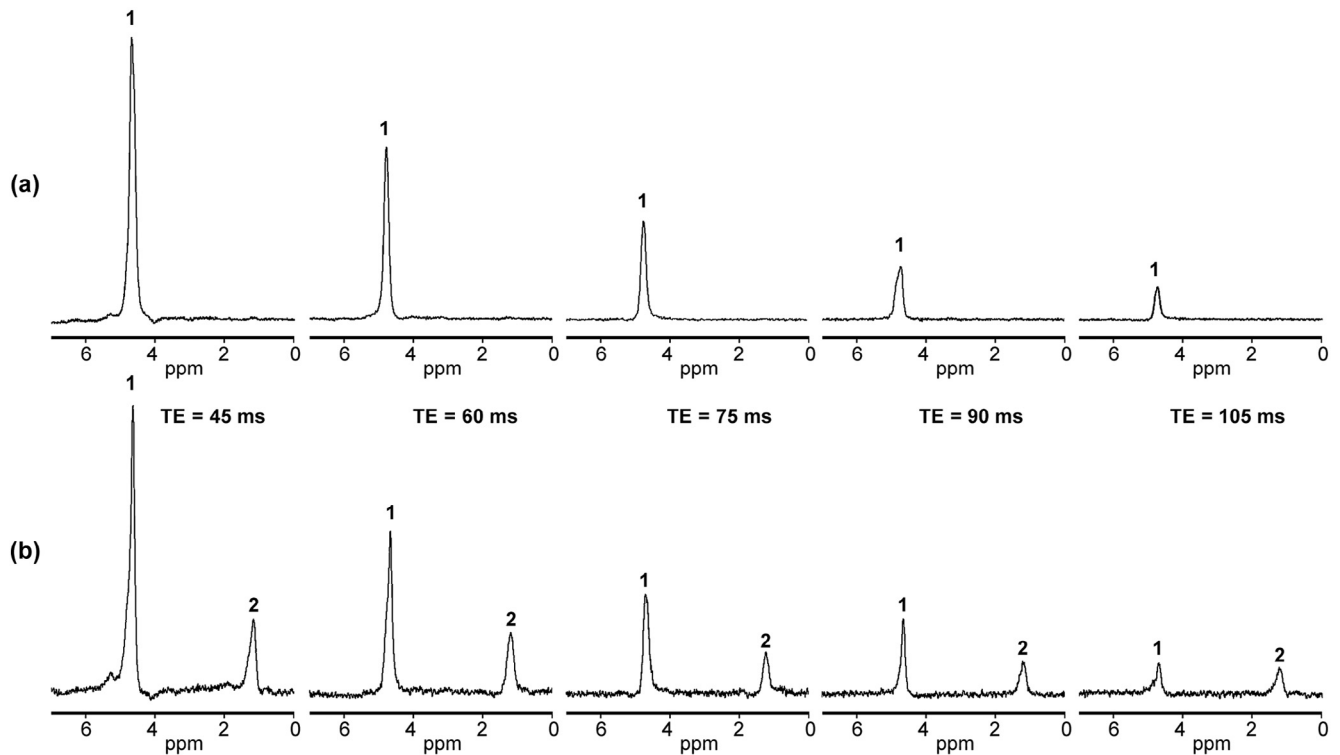
	Normal-weight Girls (n = 51)		Normal-weight Boys (n = 40)	
	Age, y	BMI SDS	Age, y	BMI SDS
Mean	13.6	0.02	12.6	0.12
Standard deviation	2.8	0.87	2.3	0.74
Minimum	8.1	-1.72	9.0	-1.70
Maximum	17.8	1.27	17.3	1.18
	Girls With Overweight (n = 62)		Boys With Overweight (n = 37)	
	Age, y	BMI SDS	Age, y	BMI SDS
Mean	13.2	1.94	13.0	1.96
Standard deviation	2.6	0.28	2.4	0.30
Minimum	7.3	1.32	9.7	1.31
Maximum	17.8	2.32	17.9	2.32
	Girls With Obesity (n = 122)		Boys With Obesity (n = 108)	
	Age, y	BMI SDS	Age, y	BMI SDS
Mean	13.6	2.82	13.0	3.00
Standard deviation	2.2	0.36	1.9	0.40
Minimum	8.8	2.34	8.6	2.33
Maximum	17.9	4.18	17.3	4.11

using SENSE Cardiac coil. T2-weighted turbo spin echo (TSE) coronal and axial slices through the upper abdomen were acquired for positioning the spectroscopy volume of interest (VOI). Parameters for the TSE sequence were as follows: TSE factor = 93, repetition time (TR) = 2182 ms, slice thickness = 7 mm, and echo time (TE) = 80 ms. Spectroscopy VOI (11 mm × 11 mm × 11 mm) was positioned in the right lobe of the liver, avoiding major blood vessels and intrahepatic bile ducts according to TSE images. A single voxel spectrum without water saturation was recorded using a point resolved spectroscopy (PRESS) sequence with the following parameters: TR = 4000 ms, spectral bandwidth = 2000 Hz, 1024 points, and 32 averages. A series of TE (45, 60, 75, 90 and 105 ms) was applied in every patient to compensate the result for T2 relaxation.

The PRESS sequence was used instead of the stimulated echo acquisition mode, because it compensates for extra dephasing due to local magnetic inhomogeneities and therefore allows for the measurement of T2 rather than T2\* values. In general, both stimulated echo acquisition mode and PRESS sequences are influenced by J-coupling effects, resulting in an additional signal modulation for CH<sub>2</sub> groups with first out-of-phase interference at approximately 60–80 ms (21,22). The series TE from 45 to 105 ms in the present study were chosen to cover both in-phase and out-of-phase interferences and thus to average the influence of J-coupling on T2 values (22).

### Measurement of Liver Fat Content

The water peak (4.7 ppm) and the fat peak (the sum of visible lipid peaks at 0.9 ppm, 1.3 ppm, and 1.6 ppm) of the acquired



**Figure 1.** Proton point resolved spectroscopy ( $^1\text{H}$  PRESS) liver spectra with echo time (TE) = 45, 60, 75, 90, and 105 ms: **(a)** 11.6-year-old normal-weight girl with body mass index standard deviation score (BMI SDS) =  $-0.91$ ; **(b)** 11.1-year-old obese girl with BMI SDS =  $4.18$ . A single water signal (1) is observed in **(a)**. Both water (1) and fat (2) signals are present in **(b)**. The corresponding liver fat signal fraction (LFSF) was calculated as 0% in **(a)** and 14% in **(b)**.

spectra were fitted to obtain their areas using a standard post-processing protocol for fitting metabolite peak areas available at the MR imaging system. The liver fat signal fraction (LFSF) was calculated according to the equation:

$$\text{LFSF} = \left( \frac{\text{fat peak area at TE} = 0 \text{ ms}}{\text{fat peak area at TE} = 0 \text{ ms} + \text{water peak area at TE} = 0 \text{ ms}} \right) \times 100.$$

Peak areas at TE = 0 ms were corrected for T2 relaxation effects for each peak using an exponential least-square fitting algorithm to the peak areas with the series of TE as described earlier (23). TR of 4 seconds was considered sufficiently long to avoid influence of T1 relaxation in the postprocessing calculations. Figure 1 shows examples of MR spectra with normal hepatic fat content and with excess hepatic fat content.

Taking into account the lipid peaks in the 3.0–5.5 ppm region, the absolute mass LFC was calculated according to (13,24–26):

$$\text{LFC} = 0.856 \times \left( \left[ \frac{\text{LFSF}}{100} \right] \left[ 1.138 - 0.339 \times \left\{ \frac{\text{LFSF}}{100} \right\} \right] \right)$$

Data postprocessing was performed by a senior experienced MR physicist.

### Statistical Analysis

Mathematical and statistical calculations were performed using Microsoft Excel and MATLAB software. Quantitative variables

were processed to give group mean values, standard deviations, a minimum, and a maximum. Pearson correlation coefficient,  $r$ , was used to describe correlations. Kruskal-Wallis test was used to describe differences between groups. Statistical significance was at a  $P$  value below .05.

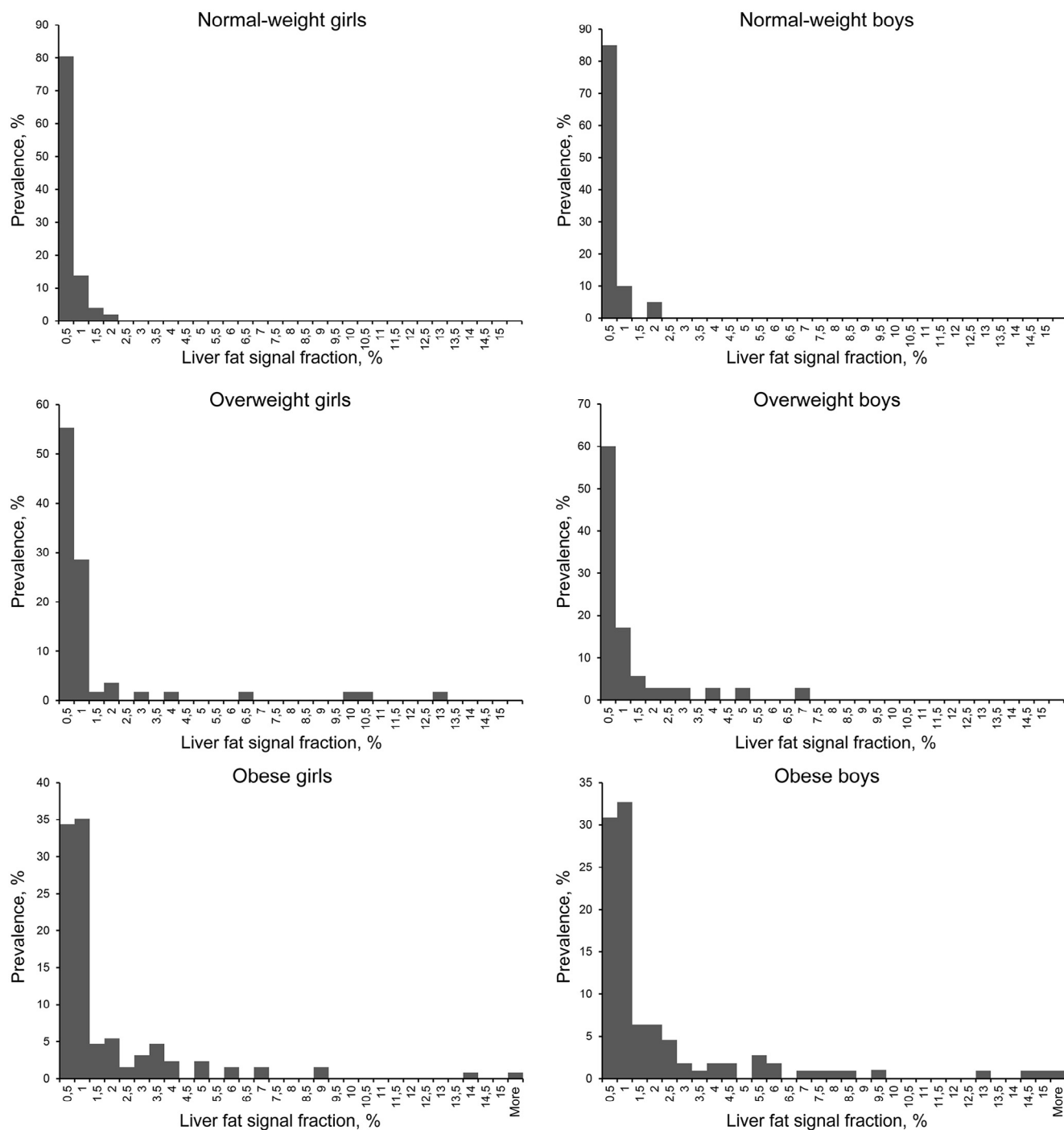
## RESULTS

The distribution of LFSF in the study cohort is shown in Figure 2. The maximum observed value of LFSF in the normal-weight group was 2.0%. The corresponding maximum observed LFC value was 1.5%. Based on this cutoff value, the prevalence of abnormal liver fat is shown in Table 2.

In average, the LFSF values were highest in the boys and girls with obesity and lowest in the normal-weight boys and girls (Fig 3). The corresponding data are shown in Table 3. The Kruskal-Wallis test showed the following: (1) significant difference ( $P < 0.05$ ) between the normal-weight, the overweight,

**TABLE 2. Prevalence of Hepatic Steatosis (Liver Fat Signal Fraction [LFSF] Over 2%; Corresponding Absolute Mass Concentration of Liver Fat [LFC] Over 1.5%) in the Overweight and Obese Study Groups**

	Girls	Boys
Overweight	11%	16%
Obese	27%	32%



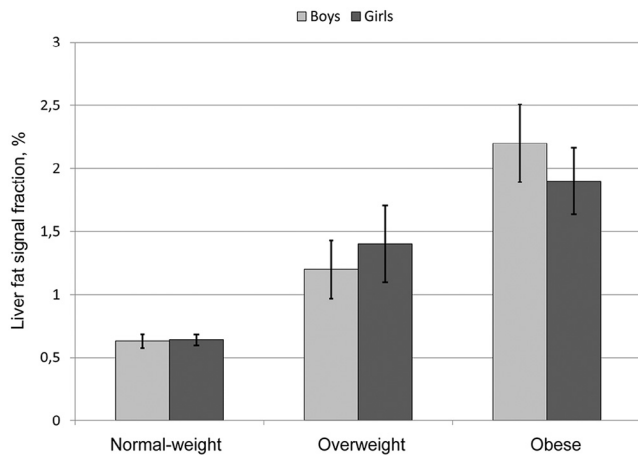
**Figure 2.** Distribution of liver fat signal fraction (LFSF) in the study cohort.

and the obese groups in both girls and boys; (2) no significant difference between the girls and the boys in the normal-weight ( $P = 0.73$ ), the overweight ( $P = 0.86$ ), or the obese ( $P = 0.38$ ) groups. Poor correlation was observed between the LFSF and the BMI SDS within the study groups (Table 4).

**DISCUSSION**

A number of MRS studies have been devoted to the assessment of hepatic steatosis, but there is no consensus on the

cutoff values (10,11,13,14). Typically, the MRS cutoff value has been set to 5% (27), as defined by the gold standard: liver biopsy (3,4). Quantification of hepatic steatosis in the groups <5%, 5%–10%, 10%–20%, and 20%–30% for both MRS and histologic examinations has shown strong correlations in adult liver donors (10). The cutoff value of 5.6% was found in a large cohort of adult subjects without liver disease or risk factors for hepatic steatosis (24). Five percent was used as the cutoff value for MRS measured liver fat in the study where MRS was compared to histologic methods in adults with liver



**Figure 3.** Mean liver fat signal fraction (LFSF) and standard errors of the mean (error bars) in normal-weight, overweight, and obese children and adolescents.

**TABLE 3. Mean and Standard Errors of the Mean Values (SD) of Liver Fat Signal Fraction (LFSF) and the Absolute Mass Concentration of Liver Fat (LFC) in the Study Groups**

	LFSF, %	LFC, %
	Mean (SD)	Mean (SD)
Normal-weight girls ( <i>n</i> = 51)	0.6 (0.04)	0.5 (0.03)
Girls with overweight ( <i>n</i> = 62)	1.4 (0.30)	1.1 (0.24)
Girls with obesity ( <i>n</i> = 122)	1.9 (0.26)	1.4 (0.21)
Normal-weight boys ( <i>n</i> = 40)	0.6 (0.05)	0.5 (0.04)
Boys with overweight ( <i>n</i> = 37)	1.2 (0.23)	0.9 (0.16)
Boys with obesity ( <i>n</i> = 108)	2.2 (0.31)	1.7 (0.24)

**TABLE 4. Correlation Between Liver Fat Signal Fraction (LFSF) and Body Mass Index Standard Deviation Score (BMI SDS) in the Study Groups**

	Girls	Boys
Normal-weight	<i>r</i> = 0.014, <i>P</i> = .9	<i>r</i> = 0.15, <i>P</i> = .36
Overweight	<i>r</i> = 0.22, <i>P</i> = .11	<i>r</i> = 0.17, <i>P</i> = .33
Obese	<i>r</i> = 0.38, <i>P</i> = .0001	<i>r</i> = 0.05, <i>P</i> = .63

disorders (9). This study also showed that histologic estimation of the percentage of hepatocytes containing fat vesicles is 2.5-fold higher than the fat fraction obtained by MRS, suggesting that the 5% cutoff value used for MRS should be reduced (9). The MRS cutoff value of 3.1% was measured in a group of adult subjects with chronic hepatitis C by comparison to histologic grading and biochemical analysis of liver biopsies (14). Another study with histopathologic validation reported the cutoff value for MRS measured LFC of 1.8% in adult patients undergoing liver resection (28). The variation of cutoff values in different studies can be explained by different subject groups, acquisition parameters, and fat fraction calculations. In the present study, we observed the

difference between normal-weight children and those with overweight and obesity. None of the normal-weight children had an LFSF higher than 2% (LFC = 1.5%). To avoid possible misinterpretations of different approaches for calculation of LFC, we showed both the LFSF and the LFC results. The cutoff value of LFSF = 2% (LFC = 1.5%) obtained in the present study, by comparison between children and adolescents with normal-weight and overweight or obesity, is close to the cutoff value of LFC = 1.8% suggested by van Werven et al., where the LFC was calculated using a similar methodology as in the present study, although in adults (28). Whether the same cutoff value should apply for both normal-weight children and normal-weight adults is subject for further investigation.

Only few publications mention a cutoff value for absolute mass LFC measured with <sup>1</sup>H MRS in children and adolescents (12,13,15). In two studies (13,15), the liver steatosis was assessed in groups of correspondingly 104 and 119 children with severe obesity with the cutoff value 1.8%. The pilot study (12) reported LFSF results for six moderately obese boys and five age-matched normal-weight controls. The number of subjects in that study was very small, but the average LFSF = 1.0 ± 0.5% was measured for the children with obesity, and the average LFSF = 0.3 ± 0.4% was measured for normal-weight controls, which is close to the findings in the present study (Table 3).

The strength of the present study is its large pediatric population including the group of normal-weight, healthy children and adolescents.

The study has some limitations. There is no external reference standard for the acquired measurements and cutoff values, so the diagnosis of excessive fat content is based on MR spectroscopy results in normal-weight children and adolescents only. Although the measurements were not validated by comparison to the gold standard of histologically determined liver fat, the LFC cutoff value of 1.5% is close to the LFC cutoff value of 1.8% published previously in a study with histopathologic assessment and with similar scanner parameters and fat fraction calculations (13,15,25).

The scanning was performed during free breathing. Thus, the spectroscopy VOI was affected by respiratory movements. We chose a relatively small VOI of 11 mm × 11 mm × 11 mm positioned to avoid blood vessels and intrahepatic bile ducts, keeping in mind the respiratory movements.

In conclusion, <sup>1</sup>H MR spectroscopy was successfully applied to obtain the cutoff value of absolute mass LFC and can be used for the diagnosis of hepatic steatosis in children and adolescents. Children and adolescents with obesity have a higher risk of hepatic steatosis than their peers with overweight.

## ACKNOWLEDGMENTS

This study was funded by the Innovation Fund Denmark (grant number 0603-00484B) and by the Region Zealand Health and Medical Research Foundation.

## REFERENCES

- Harrison SA, Day CP. Benefits of lifestyle modification in NAFLD. *Gut* 2007; 56:1760–1769.
- Bellentani S, Scaglioni F, Marino M, et al. Epidemiology of non-alcoholic fatty liver disease. *Dig Dis* 2010; 28:155–161.
- Paradis V, Bedossa P. Definition and natural history of metabolic steatosis: histology and cellular aspects. *Diabetes Metab* 2008; 34:638–642.
- Ma X, Holalkere NS, Kambadakone RA, et al. Imaging-based quantification of hepatic fat: methods and clinical applications. *Radiographics* 2009; 29:1253–1277.
- Patton HM, Lavine JE, Van Natta ML, et al. Clinical correlates of histopathology in pediatric nonalcoholic steatohepatitis. *Gastroenterology* 2008; 135:1961–1971.
- Wieckowska A, Feldstein AE. Diagnosis of nonalcoholic fatty liver disease: invasive versus noninvasive. *Semin Liver Dis* 2008; 28:386–395.
- Kobyliak N, Abenavoli L. The role of liver biopsy to assess non-alcoholic fatty liver disease. *Rev Recent Clin Trials* 2014; 9:159–169.
- Parente DB, Rodrigues RS, Paiva FF, et al. Is MR spectroscopy really the best MR-based method for the evaluation of fatty liver in diabetic patients in clinical practice? *PLoS ONE* 2014; 9:e112574; doi:10.1371/journal.pone.0112574.
- Kukuk GM, Hittatiya K, Sprinkart AM, et al. Comparison between modified Dixon MRI techniques, MR spectroscopic relaxometry, and different histologic quantification methods in the assessment of hepatic steatosis. *Eur Radiol* 2015; 25:2869–2879.
- Krishan S, Jain D, Bathina Y, et al. Non-invasive quantification of hepatic steatosis in living, related liver donors using dual-echo Dixon imaging and single-voxel proton spectroscopy. *Clin Radiol* 2016; 71:58–63.
- Rehm JL, Wolfgram PM, Hernando D, et al. Proton density fat-fraction is an accurate biomarker of hepatic steatosis in adolescent girls and young women. *Eur Radiol* 2015; 25:2921–2930.
- Lange T, Buechert M, Baumstark MW, et al. Value of MRI and MRS fat measurements to complement conventional screening methods for childhood obesity. *J Magn Reson Imaging* 2015; 42:1214–1222.
- Bohte AE, Koot BG, van der Baan-Slootweg OH, et al. US cannot be used to predict the presence or severity of hepatic steatosis in severely obese adolescents. *Radiology* 2012; 262:327–334.
- Krssák M, Hofer H, Wrba F, et al. Non-invasive assessment of hepatic fat accumulation in chronic hepatitis C by <sup>1</sup>H magnetic resonance spectroscopy. *Eur J Radiol* 2010; 74:e60–e66.
- Koot BG, van der Baan-Slootweg OH, Bohte AE, et al. Accuracy of prediction scores and novel biomarkers for predicting nonalcoholic fatty liver disease in obese children. *Obesity (Silver Spring)* 2013; 21:583–590.
- Holm JC, Gamborg M, Bille DS, et al. Chronic care treatment of obese children and adolescents. *Int J Pediatr Obes* 2011; 6:188–196.
- Fonvig CE, Chabanova E, Andersson EA, et al. <sup>1</sup>H-MRS measured ectopic fat in liver and muscle in Danish lean and obese children and adolescents. *PLoS ONE* 2015; 10:e0135018; doi:10.1371/journal.pone.0135018.
- Fonvig CE, Chabanova E, Ohrt JD, et al. Multidisciplinary care of obese children and adolescents for one year reduces ectopic fat content in liver and skeletal muscle. *BMC Pediatr* 2015; 15:196. doi:10.1186/s12887-015-0513-6.
- Nysom K, Molgaard C, Hutchings B, et al. Body mass index of 0 to 45-year-old Danes: reference values and comparison with published European reference values. *Int J Obes Relat Metab Disord* 2001; 25:177–184.
- Cole TJ, Green PJ. Smoothing reference centile curves: the LMS method and penalized likelihood. *Stat Med* 1992; 11:1305–1319.
- Hamilton G, Middleton MS, Bydder M, et al. Effect of PRESS and STEAM sequences on magnetic resonance spectroscopic liver fat quantification. *J Magn Reson Imaging* 2009; 30:145–152.
- Yahya A, Fallone BG. T<sub>2</sub> determination of the J-coupled methyl protons of lipids: in vivo illustration with tibial bone marrow at 3 T. *J Magn Reson Imaging* 2010; 31:1514–1521.
- Chabanova E, Bille DS, Thisted E, et al. MR spectroscopy of liver in overweight children and adolescents: investigation of <sup>1</sup>H T<sub>2</sub> relaxation times at 3T. *Eur J Radiol* 2012; 81:811–814.
- Szczepaniak LS, Nurenberg P, Leonard D, et al. Magnetic resonance spectroscopy to measure hepatic triglyceride content: prevalence of hepatic steatosis in the general population. *Am J Physiol Endocrinol Metab* 2005; 288:E462–E468.
- Longo R, Pollesello P, Ricci C, et al. Proton MR spectroscopy in quantitative in vivo determination of fat content in human liver steatosis. *J Magn Reson Imaging* 1995; 5:281–285.
- Hamilton G, Yokoo T, Bydder M, et al. In vivo characterization of the liver fat <sup>1</sup>H MR spectrum. *NMR Biomed* 2011; 24:784–790.
- Hetterich H, Bayerl C, Peters A, et al. Feasibility of a three-step magnetic resonance imaging approach for the assessment of hepatic steatosis in an asymptomatic study population. *Eur Radiol* 2016; 26:1895–1904.
- van Werven JR, Marsman HA, Nederveen AJ, et al. Assessment of hepatic steatosis in patients undergoing liver resection: comparison of US, CT, T<sub>1</sub>-weighted dual-echo MR imaging, and point-resolved <sup>1</sup>H MR spectroscopy. *Radiology* 2010; 256:159–168.